



**LANDESKRANKENHAUS FELDKIRCH**

*Akademisches Lehrkrankenhaus*



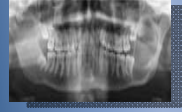

# ÜBERSICHT ÜBER DIE LEISTUNGEN DER ABTEILUNG FÜR MKG-CHIRURGIE

Oliver PLODER

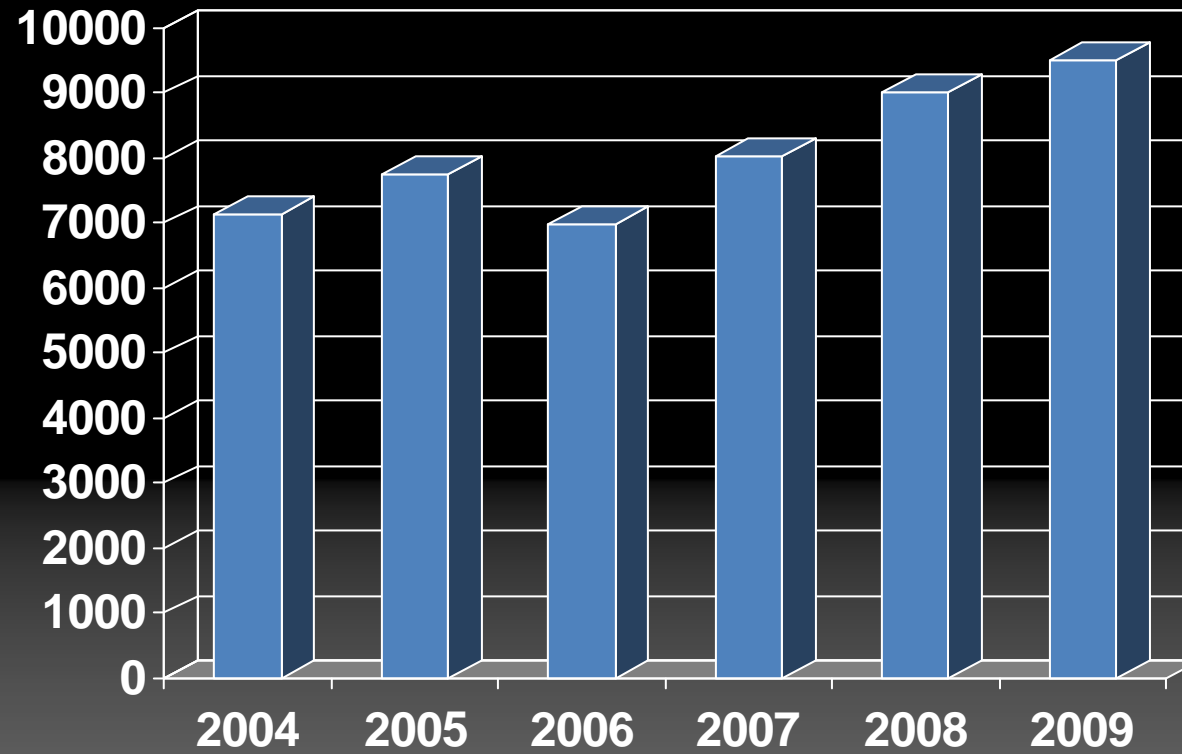
Abteilung für MKG-Chirurgie

Universitäres Lehrkrankenhaus Feldkirch

ÜBERBLICK

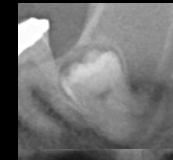

# Ambulanz



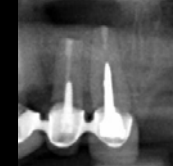# Dentoalveoläre Chirurgie

✓ Weisheitszahnentfernung



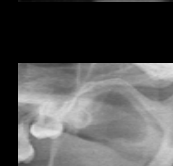1.647

✓ Wurzelspitzenresektion



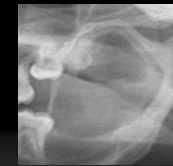103

✓ Extraktionen



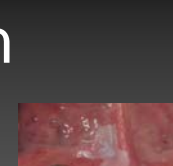
206

✓ Zysten und benigne Tumoren



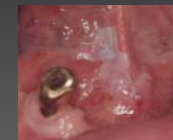30

✓ Freilegung von retinierten Zähnen

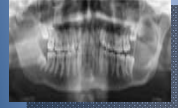





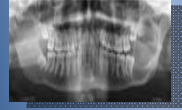


20

✓ Mundschleimhauterkrankungen

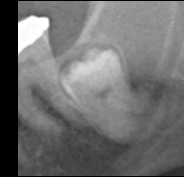

37





# Weisheitszahnentfernung



Möglichkeiten

Lokalnästhesie

Sedoanalgesie

Narkose



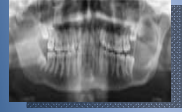


ambulant

stationär

Wann am Besten

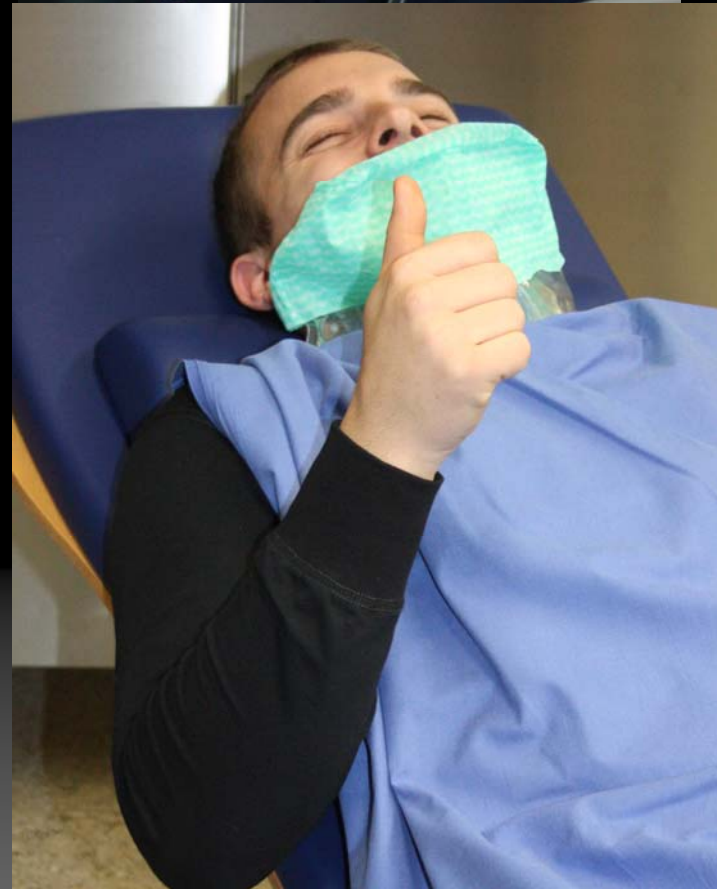Indikation

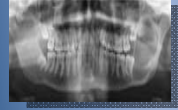


Gegenkiefer?



# Sedoanalgesie

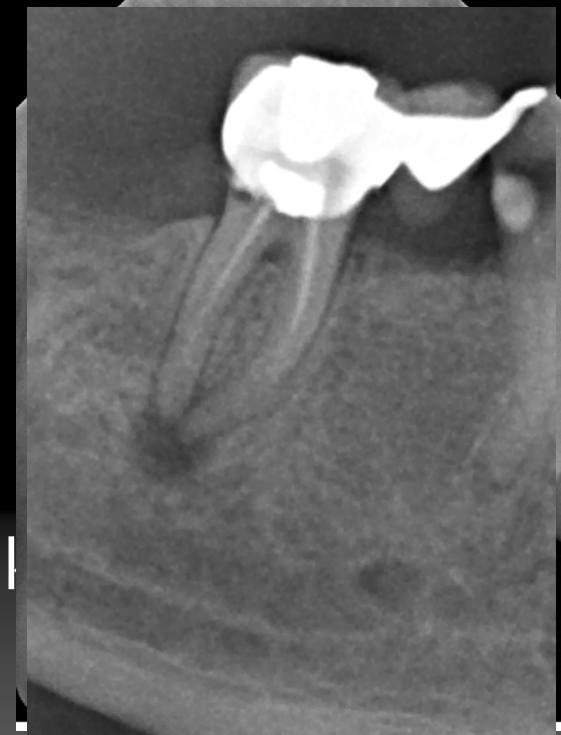- Ambulanter Eingriff
- Anästhesieteam
- Propofol® und Ultiva®
- selten Larynxmaske
- Selbstbehalt

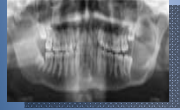





# Wurzelspitzenresektion

- orthograde Aufbereitung
- Retrograde Aufbereitung
  - ausreichende Endo, Revision?
  - Aufwand (Piezo, Laser, Mikroschliff)
  - Ultimo ratio (Frakturen)

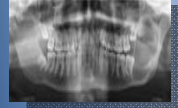



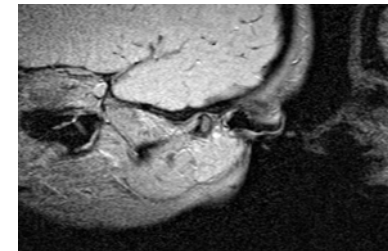
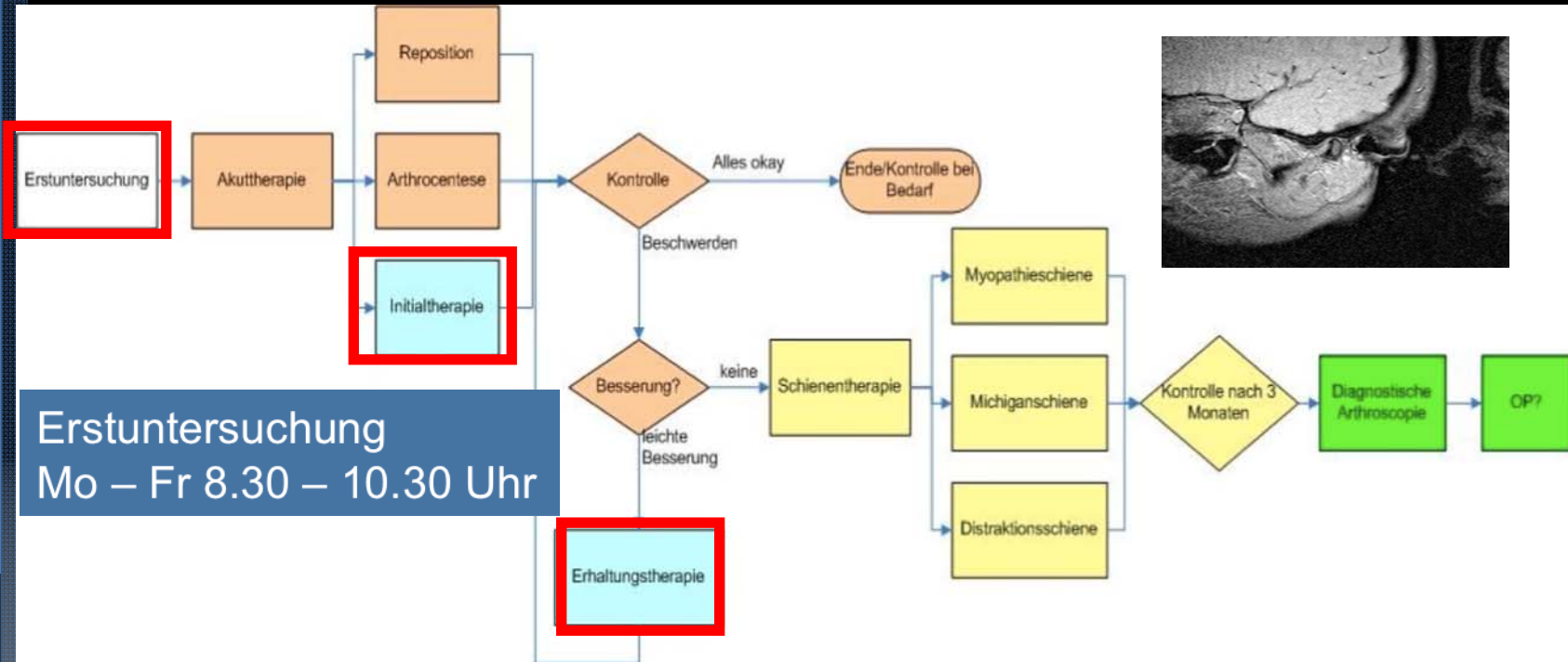




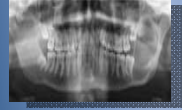


# Wurzelspitzenresektion

- orthograde Aufbereitung
- Retrograde Aufbereitung
  - ausreichende Endo, Revision?
  - Aufwand (Piezo, Laser, Mikroskop)
  - Ultimo ratio (Frakturen)

# Kiefergelenksambulanz







# Zahnärztliche Sanierung in Narkose

- Bregenz, Bludenz, Dornbirn, Feldkirch
- Externe Zahnärzte
- Feldkirch:
  - Begutachtung in den Ordinationen
  - Kinder < 8 Jahre
  - Behinderte PatientenInnen
  - Tageschirurgisch



**Mund-, Kiefer- und Gesichtschirurgie  
Akademisches Lehrkrankenhaus Feldkirch**

